

# ANESTHESIOLOGY

## Quantitative Lung Ultrasound: Technical Aspects and Clinical Applications

Silvia Mongodi, M.D., M.Sc., Ph.D.,  
Daniele De Luca, M.D., Ph.D., Andrea Colombo, M.D.,  
Andrea Stella, M.D., Erminio Santangelo, M.D.,  
Francesco Corradi, M.D., Luna Gargani, M.D., Ph.D.,  
Serena Roviada, M.D., Giovanni Volpicelli, M.D.,  
Bélaïd Bouhemad, M.D., Ph.D., Francesco Mojoli, M.D.

*ANESTHESIOLOGY* 2021; 134:949–65

Lung ultrasound has been increasingly used in recent years for the assessment of the critically ill.<sup>1–4</sup> The interpretation of artifacts (A- and B-lines), analysis of the pleura, and the visualization of real images (consolidations and pleural effusions) significantly improve the differential diagnosis of acute respiratory failure.<sup>5,6</sup> An impact on therapeutic management<sup>7</sup> and reduction of chest x-ray films in intensive care units (ICUs)<sup>8,9</sup> has also been suggested. Lung ultrasound has now moved on from the critically ill, spreading to chronic patients for assessing lung involvement in chronic heart failure,<sup>10–12</sup> hemodialysis,<sup>13</sup> and autoimmune diseases.<sup>14</sup>

Although qualitative lung ultrasound gives a morphological assessment of the lung, with the identification of different etiologies of lung failure, a quantitative approach is essential to switch from diagnostic to monitoring use. An *in vitro* study showed that the number and coalescence of B-lines correlated with lung density,<sup>15</sup> and similar patterns were observed in the progressively deaerated lung during one-lung ventilation.<sup>16</sup>

This led to the hypothesis that loss of lung aeration could be quantified on the basis of the number and type of artifacts visualized. Many scoring systems have since been

### ABSTRACT

Lung ultrasound is increasingly used in emergency departments, medical wards, and critical care units—adult, pediatric, and neonatal. *In vitro* and *in vivo* studies show that the number and type of artifacts visualized change with lung density. This has led to the idea of a quantitative lung ultrasound approach, opening up new prospects for use not only as a diagnostic but also as a monitoring tool. Consequently, the multiple scoring systems proposed in the last few years have different technical approaches and specific clinical indications, adaptable for more or less time-dependent patients. However, multiple scoring systems may generate confusion among physicians aiming at introducing lung ultrasound in their clinical practice. This review describes the various lung ultrasound scoring systems and aims to clarify their use in different settings, focusing on technical aspects, validation with reference techniques, and clinical applications.

(*ANESTHESIOLOGY* 2021; 134:949–65)

developed in different clinical contexts (table 1). Multiple quantitative approaches may help in adapting the technique to different scenarios but may also give rise to confusion among physicians. This review describes the different scoring techniques, specific technical aspects, and appropriate clinical applications.

### The Approach to the Acute Medical Patient

#### Technical Aspects

Correlations between ultrasound findings and a decrease in lung aeration are attracting attention because lung ultrasound has become easily accessible, quick, and repeatable at the bedside thanks to handheld devices. Any probe is suitable for lung ultrasound examination (fig. 1), and convex and microconvex probes are the most frequently used in emergency departments.<sup>37,43–45</sup> The probe is usually oriented longitudinally—perpendicular to the ribs—because this allows clear identification of the bat sign, corresponding to the upper and lower ribs, and the pleural line (fig. 2).

The scanning technique in the emergency setting comprises eight zones, four chest areas per hemithorax: upper and lower anterior and upper and lower lateral areas (fig. 3).<sup>43</sup> In an emergency department, the examination focuses on the recognition of B-positive areas, defined by

This article is featured in "This Month in Anesthesiology," page A1.

Submitted for publication September 23, 2020. Accepted for publication February 19, 2021. Published online first on April 5, 2021. From Anesthesia and Intensive Care, San Matteo Hospital, Pavia, Italy (S.M., F.M.); the Division of Pediatrics and Neonatal Critical Care, A. Béclère Medical Center, Paris-Saclay University Hospitals, Public assistance – Paris Hospitals, Paris, France (D.D.L.); the Physiopathology and Therapeutic Innovation Unit, Paris-Saclay University, Paris, France (D.D.L.); the Department of Clinical-Surgical, Diagnostic and Pediatric Sciences, Unit of Anesthesia and Intensive Care, University of Pavia, Pavia, Italy (A.C., A.S., F.M.); the Department of Translational Medicine, University of Eastern Piedmont, Novara, Italy (E.S.); the Interdepartmental Intensive Care Unit, Nuovo Santa Chiara Hospital, Pisa, Italy (F.C.); the Department of Anesthesiology, University of Pisa, Pisa, Italy (F.C.); the Institute of Clinical Physiology, National Research Council, Pisa, Italy (L.G.); the Department of Emergency Medicine, Linköping University Hospital, Linköping, Sweden (S.R.); the Department of Emergency Medicine, San Luigi Gonzaga University Hospital, Torino, Italy (G.V.); Dijon and University of Burgundy Franche-Comté, Dijon Cedex, France (B.B.); and the Department of Anesthesiology and Intensive Care, University Hospital Dijon, Dijon Cedex, France (B.B.).

Copyright © 2021, the American Society of Anesthesiologists, Inc. All Rights Reserved. *Anesthesiology* 2021; 134:949–65. DOI: 10.1097/ALN.0000000000003757

the B-pattern—at least three B-lines in an intercostal space (fig. 4)—and how they change in response to procedures and medical treatments.

### Validation with Reference Techniques

Lung ultrasound findings closely correlate with extravascular lung water, measured by transpulmonary thermodilution (pulse index continuous cardiac output). The A-pattern (*i.e.*, A-lines or no more than two B-lines in an intercostal space, with visible lung sliding) predicts low extravascular lung

water, whereas the number of B-positive areas correlates with extravascular lung water. However, the association with echocardiographic measures is suggested for a correct estimate of the wedge pressure.<sup>31,37</sup>

### Acute Heart Failure

When combined with other scores, such as the Brest score, a systematic lung ultrasound evaluation improves the diagnosis of acute heart failure.<sup>32</sup> This offers a good correlation between the number of B-positive areas and

**Table 1.** Scoring Systems and Validation with Reference Techniques in the Literature for Assessing Lung Aeration

Score	Citation	Year	Reference Technique	Results
Lung ultrasound score	Bouhemad <i>et al.</i> <sup>17</sup>	2010	Computed tomography	Lung ultrasound re-aeration score greater than 5 was associated with a re-aeration of greater than 400 ml in quantitative computed tomography and a successful antimicrobial therapy in ventilator-associated pneumonia. Lung ultrasound score less than -10 was associated with a loss of aeration of greater than 400 ml in computed tomography and a failure of antibiotics. Highly significant correlation between computed tomography and ultrasound lung re-aeration.
	Bouhemad <i>et al.</i> <sup>18</sup>	2011	Pressure-volume curve	Correlation was found between PEEP-induced lung recruitment measured by pressure-volume curves and ultrasound re-aeration score. An ultrasound re-aeration score of 18 or higher was associated with a PEEP-induced lung recruitment greater than 600 ml. An ultrasound lung re-aeration score of 14 or less was associated with a PEEP-induced lung recruitment ranging from 75 to 450 ml.
	Zhao <i>et al.</i> <sup>19</sup>	2015	Extravascular lung water	Lung ultrasound score and the extravascular lung water indexed were significantly correlated in ARDS patients.
	Brat <i>et al.</i> <sup>20</sup>	2015	Neonatal oxygenation indexes	Lung ultrasound score correlates well with all the oxygenation indexes independently from gestational age. Lung ultrasound score predicts better the need for surfactant in preterm babies with gestational age of less than 34 weeks than in term and late-preterm neonates. Under a gestational age of 34 weeks, lung ultrasound score cutoff of 4 predicts surfactant need with 100% sensitivity and 61% specificity (probability of 72%).
	Caltabeloti <i>et al.</i> <sup>21</sup>	2014	Extravascular lung water	In patients with septic shock and ARDS requiring fluid resuscitation, lung ultrasound score variations were the earliest parameter detecting an increase in extravascular lung water indexed, preventing excessive fluid loading.
	Chiumello <i>et al.</i> <sup>22</sup>	2018	Computed tomography	Global lung ultrasound score was strongly associated with lung density at PEEP 5 and PEEP 15 in ARDS. Regional lung ultrasound score strongly correlated with tissue density at PEEP 5 and PEEP 15 cm H <sub>2</sub> O. Changes of global lung ultrasound score were not statistically associated with lung recruitment defined as a decrease of not aerated tissue.
	Raimondi <i>et al.</i> <sup>23</sup>	2018	Gray scale analysis, PAO <sub>2</sub> /Fio <sub>2</sub>	Simplified lung ultrasound score (neonates): a visual assessment of lung ultrasound score correlates well with PAO <sub>2</sub> /Fio <sub>2</sub> . A good correlation has been also found between oxygenation indexes and semiquantitative computerized gray scale analysis of lung ultrasound scans.
	B-lines score	Noble <i>et al.</i> <sup>24</sup>	2009	Net volume of fluid removed
Jambrik <i>et al.</i> <sup>25</sup>		2010	Lung gravimetry	Significant correlation between the wet/dry ratio and B-lines in minipigs.
Trezzi <i>et al.</i> <sup>26</sup>		2013	Clinical evaluation Inferior vena cava diameter	In asymptomatic patients, good correlation between the number of B-lines, the predialytic weight of patients, and its variation after the dialytic treatment. A correlation was found between inferior vena cava diameter variations before and after dialytic treatment and the number of B-lines.
Miglioranza <i>et al.</i> <sup>27</sup>		2013	Laboratory parameters Echocardiography Chest x-ray film Six-minute walking test	At least 15 B-lines proved to be a tool of great accuracy for diagnosis of acute decompensated heart failure, with data confirmed by a combination of diastolic dysfunction as measured by echocardiographic parameters, amino-terminal pro-brain natriuretic peptide, chest x-ray film, and 6-min walking test.
Baldi <i>et al.</i> <sup>28</sup>		2013	Computed tomography	Good correlations between the B-line score and lung weight and density, especially of the upper lobes.
Donadio <i>et al.</i> <sup>29</sup>		2015	Laboratory parameters Bioelectrical impedance analysis	A significant correlation between the number of B-lines and extracellular water index, with thoracic impedance and with brain-natriuretic peptide.
Gigante <i>et al.</i> <sup>30</sup>		2016	Computed tomography Pulmonary function test Clinical examination	Positive correlation between the number of B-lines and the high-resolution computed tomography score; negative correlation between the number of B-lines and diffusion lung capacity for carbon monoxide. The number of B-lines increases along with the progression of the capillaroscopic damage. A statistically significant difference in the number of B-lines was found between patients with and without digital ulcers.
Torino <i>et al.</i> <sup>13</sup>		2016	Clinical evaluation of volume status Lung auscultation	Poor agreement between B-lines and pulmonary crackles in both analyses considering the average number of B-lines and the average grading of crackles and peripheral edema across the observation period or the whole series of measurements considered individually.
Anile <i>et al.</i> <sup>31</sup>	2017	Extravascular lung water	A significant correlation between the number of lung quadrants positive for B-lines and indexed extravascular lung water using both actual body weight and predicted body weight.	

(Continued)

Table 1. (Continued)

Score	Citation	Year	Reference Technique	Results
B-lines score	Buessler <i>et al.</i> <sup>32</sup>	2020	Brest score	Comparison of 4-, 6-, 8-, and 28-point methods. Each method provided significant added value to the Brest score as assessed by changes in the C-index; the highest increase in the C-index was observed for the 6-point method and the 8-point method.
	Man <i>et al.</i> <sup>33</sup>	2019	Computed tomography	Good correlation between the total number of B-lines score and the high-resolution computed tomography simplified score and also between the total number of positive chest areas score and the high-resolution computed tomography score.
	Gasperini <i>et al.</i> <sup>34</sup>	2020	Computed tomography Pulmonary function test Clinical examination	In multiple regression analysis, positive correlation exists between the number of B-lines and high-resolution computed tomography score. Negative correlation exists between number of B-lines and diffusion lung capacity for carbon monoxide and forced vital capacity. The number of B-lines significantly increased with progression of digital microvascular damage. At 12 months, a positive correlation exists between the number of B-lines and the $\delta$ of diffusion lung capacity for carbon monoxide.
	Mallamaci <i>et al.</i> <sup>35</sup>	2010	Bioelectrical impedance analysis Anatomical and functional echocardiographic parameters	Lung water excess was unrelated to hydration status but was strongly associated with New York Heart Association classification, left ventricular ejection fraction, early filling to early diastolic mitral annular velocity, left atrial volume, and pulmonary pressure.
	Li <i>et al.</i> <sup>36</sup>	2018	Chest x-ray film Laboratory parameters Clinical parameters	Positive linear correlations were found between the lung B-lines score and the studied echocardiographic parameters, New York Heart Association classification, radiologic score, and amino-terminal pro-brain natriuretic peptide.
B+ areas	Volpicelli <i>et al.</i> <sup>37</sup>	2014	Extravascular lung water Wedge pressure	Wedge pressure of 18 mmHg or less was predicted by the A-pattern with 85.7% sensitivity and 40.0% specificity, whereas indexed extravascular lung water 10 ml/kg or less with 81.0 and 90.9% specificity.
	Del Rey Hurtado de Mendoza <i>et al.</i> <sup>38</sup>	2019	Chest x-ray film Extravascular lung water	Study conducted on newborns with persistent pulmonary hypertension of the newborn. Lung ultrasound showed a better sensitivity and specificity than chest x-ray film in identifying patients with nonparenchymal lung disease.
Automatic lung ultrasound	Corradi <i>et al.</i> <sup>39</sup>	2013	Computed tomography	In 10 isolated bovine lung lobes, video-based mean lung ultrasound intensity was strongly correlated with extravascular lung water density but weakly correlated with mean computed tomography attenuation and physical density.
	Corradi <i>et al.</i> <sup>40</sup>	2015	Computed tomography Chest x-ray film	Quantitative ultrasonography showed higher sensitivity (93%), specificity (95%), and diagnostic accuracy (94%) than chest x-ray film (64, 80, and 69%, respectively), visual ultrasonography (68, 95, and 77%, respectively), or their combination (77, 75, and 77%, respectively) for the detection of community-acquired pneumonia.
	Corradi <i>et al.</i> <sup>41</sup>	2016	Extravascular lung water Wedge pressure B-lines score	Wedge pressure significantly and strongly correlated with automated quantitative lung ultrasound but weakly correlated with B-lines score. Extravascular lung water was significantly and more strongly correlated with automated quantitative lung ultrasound than with B-lines score. At high PEEP, only automated quantitative lung ultrasound provides data that are significantly correlated with wedge pressure and extravascular lung water.
	Brusasco <i>et al.</i> <sup>42</sup>	2019	Extravascular lung water	Automated quantitative scan showed a stronger association with extravascular lung water than coalescence-based lung ultrasound score and B-lines score but a lower association than quantitative-based lung ultrasound score.

ARDS, acute respiratory distress syndrome;  $FiO_2$ , fractional inspired oxygen tension;  $PAO_2$ , partial pressure of alveolar oxygen; PEEP, positive end-expiratory pressure.

left ventricular diastolic dysfunction, pulmonary artery hypertension, severity of mitral regurgitation, and amino-terminal pro-brain natriuretic peptide.<sup>36</sup> As a mirror of the air/fluid ratio in the pulmonary parenchyma, lung ultrasound can also help guide fluid resuscitation, avoiding the risks of harmful fluid overload on lung function.<sup>4,44,46,47</sup>






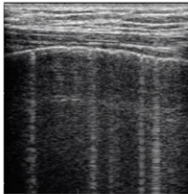
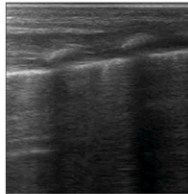
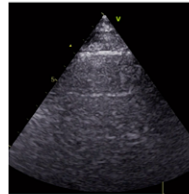
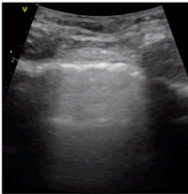
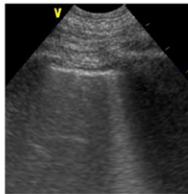
Heart failure signs and symptoms become evident late, and their disappearance is not always linked to real improvement. This may result in incorrect titration of therapy and inappropriate early discharge of the patient.<sup>44</sup>

Advanced invasive methods for assessing extravascular volume, although reliable,<sup>47</sup> do not lend themselves well to the emergency department. Nowadays, chest x-ray films and the plasma brain natriuretic peptide concentration are

considered standard noninvasive methods for staging acute decompensated heart failure. Volpicelli *et al.* found concordance between a decrease in B-positive areas and a reduction of extravascular lung water, as well as improvements in chest x-ray films and plasma brain natriuretic peptide.<sup>46</sup> Further studies in patients under hemodialysis found significant correlations between the reduction of B-positive areas and body weight loss during hemodialysis.<sup>29,48</sup>

### Pulmonary Primary Infection

In the patient presenting with acute respiratory failure, the total number of B-lines assessed in the four conventional areas per hemithorax has been used to differentiate pulmonary primary infection from overinfection in

	LINEAR	HOCKEY STICK	PHASED-ARRAY	CONVEX	MICRO-CONVEX
					
					
<b>FREQUENCY:</b>	HIGH	VERY HIGH	LOW	LOW	WIDE RANGE
<b>SUPERFICIAL RESOLUTION:</b>	HIGH	VERY HIGH	LOW	LOW	MODERATE
<b>PENETRATION CAPACITY:</b>	LOW	VERY LOW	HIGH	HIGH	HIGH
<b>BEST FOR:</b>	PLEURA ARTIFACTS	PLEURA ARTIFACTS	CONSOLIDATIONS EFFUSIONS	CONSOLIDATIONS EFFUSIONS	CONSOLIDATIONS EFFUSIONS
<b>PREFERRED SETTING:</b>	CRITICAL CARE	NEONATAL CRITICAL CARE	CHRONIC DISEASE	EMERGENCY Department	CRITICAL CARE
<b>AVAILABILITY:</b>	FREQUENT	FREQUENT in PEDIATRIC	FREQUENT	FREQUENT	UNFREQUENT

**Fig. 1.** Main features of the ultrasound transducers most commonly used for lung assessment.

decompensated cardiac failure: the latter typically has significantly more B-lines.<sup>49</sup> A simplified lung ultrasound scoring system, similar to the one used in ICUs (see the section “The Critically Ill Patient”) but limited to three areas per hemithorax, can also help predict hospital mortality of these septic patients.<sup>50</sup>

## The Critically Ill Patient

### Technical Aspects

In the ICU, the lung ultrasound score is the most frequently used scoring system. It distinguishes four progressive steps of loss of aeration according to the artifacts visualized in a scan: score 0, normal aeration (A-lines or no more than two B-lines); score 1, moderate loss of aeration (three or more well-spaced B-lines); score 2, severe loss of aeration (coalescent B-lines); and score 3, complete loss of aeration (tissue-like pattern; figs. 4 and 5). These steps were previously referred to as N, B1, B2, and C. This score is computed in six regions per hemithorax: anterior, lateral, and posterior fields are identified by sternum, anterior, and posterior axillary lines; each field is divided into superior and inferior regions (fig. 3).

It is suggested to start in the anterior fields with a linear probe and then to switch to a phased-array or a convex probe if consolidation is visualized. A transversal approach, aligned with the intercostal space, would be preferred once the pleura has been correctly identified: it visualizes a wider pleura and more artifacts (fig. 2).<sup>51</sup>



The lung ultrasound score is easily learned (25 examinations) and repeatable, for both image acquisition and

interpretation.<sup>22,51</sup> Complete examinations take 10 to 15 min.<sup>52</sup> A three-level competence pyramid was recently suggested: academic teacher with several publications in the field; more than 25 supervised procedures and 200 non-supervised procedures; and at least 25 supervised procedures and less than 200 nonsupervised procedures).<sup>53</sup> The authors suggest daily practice at the beginning of the learning curve.

### Validation with Reference Techniques

Regional scores showed strong correlations with lung density measured by quantitative computed tomography.<sup>22</sup> The global lung ultrasound score is computed as the sum of regional scores; therefore, the total score ranges from 0 to 36. It showed good linear correlations with extravascular lung water measured by pulse index continuous cardiac output<sup>19</sup> and a strong association with lung density by quantitative computed tomography,<sup>22,28</sup> although with a tendency to overestimate lung aeration loss in acute respiratory distress syndrome (ARDS).

A recent study suggested distinguishing moderate and severe loss of aeration (scores 1 and 2) in relation to the percentage of pleura affected by artifacts (score 2 if B-lines or subpleural consolidations in clearly 50% or more).<sup>51</sup> This may limit overestimation of loss of aeration in patients with frequent focal coalescences and nonhomogeneous diseases such as ARDS, trauma, and ventilator-associated pneumonia. This modified score had the strongest correlation with extravascular lung water compared to all the other rating systems, and included automation<sup>42</sup>; therefore, it should be the preferred strategy for regional/global lung aeration assessment and monitoring in the critically ill.

LONGITUDINAL SCAN	TRANSVERSAL SCAN
Aligned with cranio-caudal axis	Aligned with intercostal space
	
PROs	PROs
<ul style="list-style-type: none"> <li>- Easy to obtain: ideal for beginners</li> <li>- Clear identification of the pleural line: ideal in doubtful cases (for example: subcutaneous emphysema)</li> </ul>	<ul style="list-style-type: none"> <li>- Visualization of wider pleura</li> <li>- More constant visualized pleural length (between and within patients)</li> <li>- Visualization of more artefacts</li> </ul>
CONS	CONS
<ul style="list-style-type: none"> <li>- Visualization of shorter pleura</li> <li>- High pleural length variance</li> <li>- Visualization of fewer artefacts</li> </ul>	<ul style="list-style-type: none"> <li>- More technically challenging: not for beginners</li> <li>- In case of doubtful identification of the pleura: start with longitudinal and then turn the probe</li> </ul>

**Fig. 2.** Longitudinal and transversal scans of the same intercostal space. The longitudinal scan allows visualization of the bat sign—the space between two ribs—allowing certain identification of the pleural line. This approach is recommended for beginners and/or if there is any doubt about the visualization of the pleura (for example, suspected pneumothorax and subcutaneous emphysema). The transversal scan is aligned with the intercostal space, for better assessment of the lung, because a wider pleura is visualized.

## Monitoring Lung Aeration

The lung ultrasound score has been employed for monitoring lung aeration in ARDS patients receiving extracorporeal membrane oxygenation<sup>54,55</sup>; progressive reduction of the score indicates gradual recovery of the injured lung. An accurate bedside tool is of particular interest in these patients because transport to a radiology department involves high risk, and standard chest x-ray films are poorly informative in almost completely deaerated lungs.

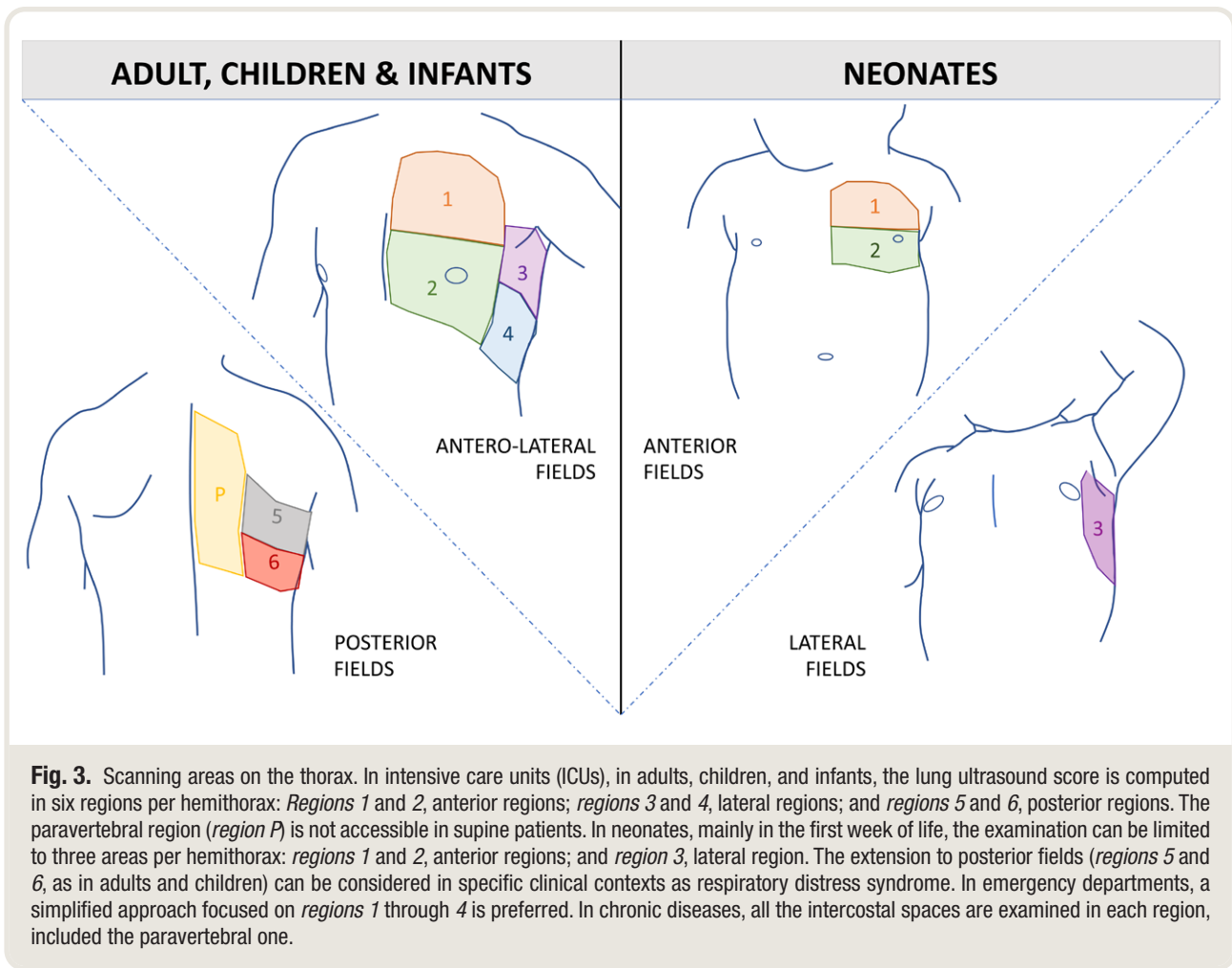
A quantitative approach can also be employed to monitor the response to treatments in the critically ill patient. In ARDS patients in shock requiring fluid resuscitation, changes in the lung ultrasound score were the earliest parameter indicating an increase in extravascular lung water as a detrimental effect of the fluid challenge.<sup>21</sup> The changes in lung aeration detected by ultrasound are seen sooner than deterioration in gas exchanges, because oxygenation can initially be improved by the transient positive impact of fluid resuscitation on hemodynamics. A reaeration score computed on the basis of the same four patterns before and after treatments modifying aeration accurately detected the changes in lung aeration induced by 7 days of antibiotics in ventilator-associated pneumonia, with significant correlations with quantitative computed tomography.<sup>17</sup>

## Personalized Mechanical Ventilation

Similarly, a quantitative approach can be useful to guide and monitor the respiratory strategy, including pronation and positive end-expiratory pressure (PEEP) titration. A personalized approach does seem to improve survival of ARDS patients, as long as the lung pattern can be accurately distinguished as focal or diffuse.<sup>56,57</sup> Focal distribution, with normal aeration in anterior fields and severe or complete loss of aeration in posterior ones, indicates response to pronation<sup>58,59</sup>: in patients with focal distribution, the lung ultrasound score changes more when they are prone. A dedicated score for posterior fields has been proposed to identify long-term responders to pronation.<sup>60</sup>

In a first study by Bouhemad *et al.*,<sup>18</sup> a significant correlation was also found between the reaeration score and PEEP-induced recruitment measured by a pressure-volume curve in a decremental PEEP trial. Patients with a diffuse pattern—*i.e.*, loss of aeration also affecting anterior fields—were more frequently PEEP responders.

The correlation between PEEP-induced recruitment and lung ultrasound scores was not confirmed in a study comparing lung ultrasound score and quantitative computed tomography: computed tomography defines recruitment as reaeration of previously not aerated tissue, whereas



**Fig. 3.** Scanning areas on the thorax. In intensive care units (ICUs), in adults, children, and infants, the lung ultrasound score is computed in six regions per hemithorax: *Regions 1 and 2*, anterior regions; *regions 3 and 4*, lateral regions; and *regions 5 and 6*, posterior regions. The paravertebral region (*region P*) is not accessible in supine patients. In neonates, mainly in the first week of life, the examination can be limited to three areas per hemithorax: *regions 1 and 2*, anterior regions; and *region 3*, lateral region. The extension to posterior fields (*regions 5 and 6*, as in adults and children) can be considered in specific clinical contexts as respiratory distress syndrome. In emergency departments, a simplified approach focused on *regions 1 through 4* is preferred. In chronic diseases, all the intercostal spaces are examined in each region, included the paravertebral one.

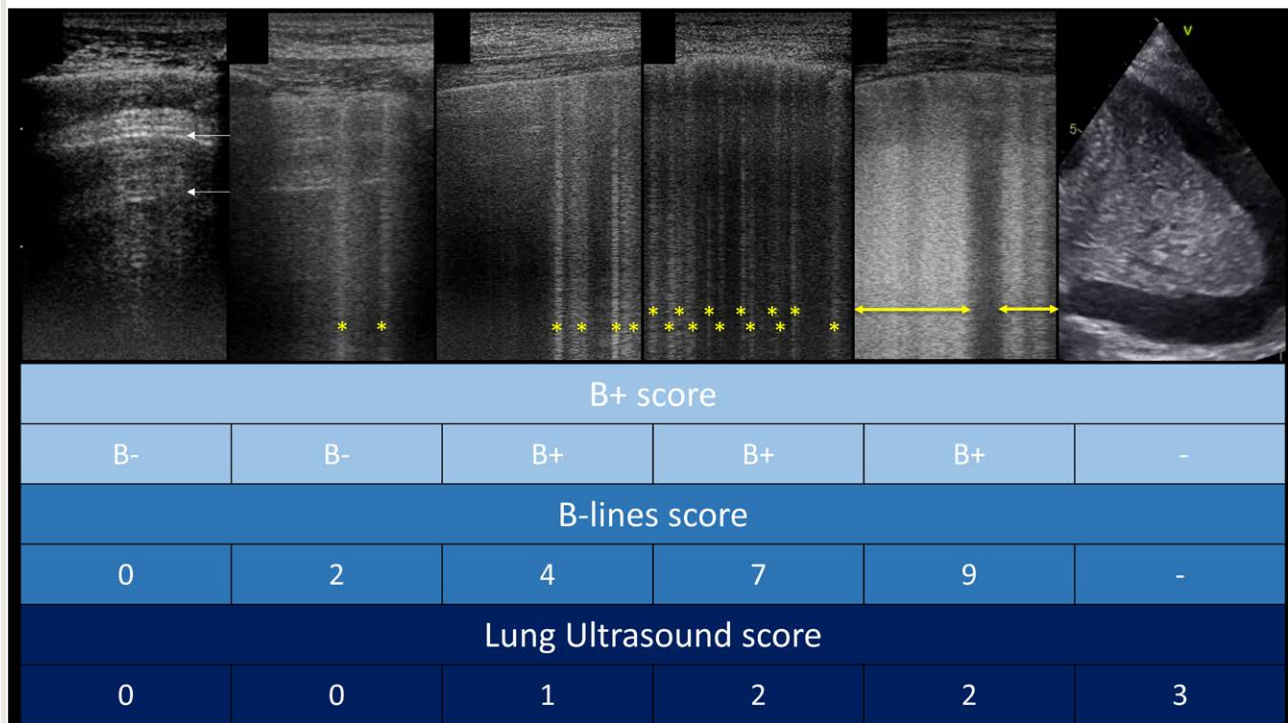
the lung ultrasound score detects any improvement in aeration, regardless of the initial state. This intrinsic difference implies the absence of any direct correlation between these two techniques, while not affecting the interest in a bedside ultrasound assessment of PEEP-induced changes in lung aeration.<sup>52</sup> For a better comparison, only changes in the regions with a tissue-like pattern should probably be considered. However, to date there are no clinical studies assessing this.

### Predicting Outcome and Weaning from Mechanical Ventilation

In terms of outcome prediction, the lung ultrasound score after 3 days of mechanical ventilation in ARDS patients predicted mortality well.<sup>19,61</sup> In postsurgical patients, a score higher than 14 at admission to the ICU identified the frailest patients with 90% specificity and predicted a prolonged need for postoperative respiratory support.<sup>62</sup>

Quantitative lung ultrasound can also be used to make weaning from mechanical ventilation more successful: computed at the end of a successful spontaneous breathing trial, the lung ultrasound score can identify patients at high

risk of extubation failure.<sup>63,64</sup> It has been suggested that the increase in lung ultrasound after a spontaneous breathing trial corresponds to weaning-induced lung edema, thus serving as an indirect measure of increased left ventricle filling pressure.<sup>65</sup> However, in a cohort of elderly patients with frequent underlying diastolic dysfunction, the increase in lung ultrasound score after a spontaneous breathing trial was not necessarily caused by increased left ventricle filling pressure, and in fact an increase in left ventricle filling pressure was not necessarily associated with an increase in extravascular lung water as measured by lung ultrasound.<sup>66</sup> The pathophysiological mechanisms underlying a worsening of lung aeration, and therefore weaning failure, include weaning-induced lung edema but also lung derecruitment caused by unsolved underlying lung disease or inadequate muscle strength. The lung ultrasound score helps detect any deterioration in lung aeration, regardless of the etiology, and is therefore a very accurate tool to identify the failing patient. A simplified approach focused on anterolateral fields has been proposed. A flowchart for approaching the patient to be weaned from mechanical ventilation is set out in figure 6.



**Fig. 4.** Ultrasound patterns and corresponding scores in different rating systems for lung aeration quantification. *White arrows*, A-lines; \*, well-spaced B-lines; *yellow double-point arrows*, coalescent B-lines.

### COVID-19 Patients

In patients with COVID-19, the lung ultrasound score predicts the severity of the disease accurately when compared to computed tomography<sup>53</sup>; a score lower than 13 corresponds to mild disease, whereas a score higher than 23 identifies severe pneumonia at admission. Lung ultrasound score can be used to monitor the progression of the disease and to predict the need for mechanical ventilation.<sup>67</sup> Pocket-size devices also offer good accuracy in the assessment of lung ultrasound scores<sup>68</sup> in COVID-19,<sup>69</sup> becoming a valuable tool as part of the clinical assessment and helping optimize the allocation of clinical resources in this pandemic.

### The Approach to the Surgical Patient in the Perioperative Setting

Although it was initially used only to rule out pneumothorax as a complication of central line placement, lung ultrasound is now attracting attention in anesthesia in clinical practice, both inside and outside the operating theater, for quantitative analysis of lung aeration. Lung ultrasound has been used to assess a wide range of perioperative pulmonary complications and to monitor lung aeration changes during general anesthesia. The technical approach is similar to that in the critically ill patient. Perioperative pulmonary complications—such as atelectasis, pneumothorax,

bronchospasm, pleural effusions, and aspiration pneumonitis—result in fact in higher mortality and greater need for health care.<sup>70,71</sup> Therefore, early detection and prompt treatment are recommended.

The computation and monitoring of lung ultrasound scores permit early detection of postoperative pulmonary complications after major abdominal surgery.<sup>72</sup> Compared to chest x-ray films and clinical examination, lung ultrasound has performed better for detecting respiratory complications (atelectasis, consolidations, alveolar–interstitial syndrome, pleural effusion, and pneumothorax) after cardiothoracic surgery.<sup>73,74</sup> Among these, intraoperative atelectasis is the substratum for postoperative lung dysfunction and further respiratory complications such as pneumonia, weaning failure, and postextubation respiratory failure.<sup>75</sup> Subclinical atelectasis has also been reported in the dependent parts of the lung immediately after induction of anesthesia. Accordingly, Monastesse *et al.*<sup>76</sup> found that the worsening of oxygenation after the induction of general anesthesia was associated with an increase in lung ultrasound score, mainly in the dependent lung regions. A modified lung ultrasound score taking more account of subpleural consolidations showed greater sensitivity in following aeration loss after pneumoperitoneum.<sup>76</sup> Similar results were obtained in children, where typical lung ultrasound signs (tissue-like pattern, subpleural consolidations, and abolished

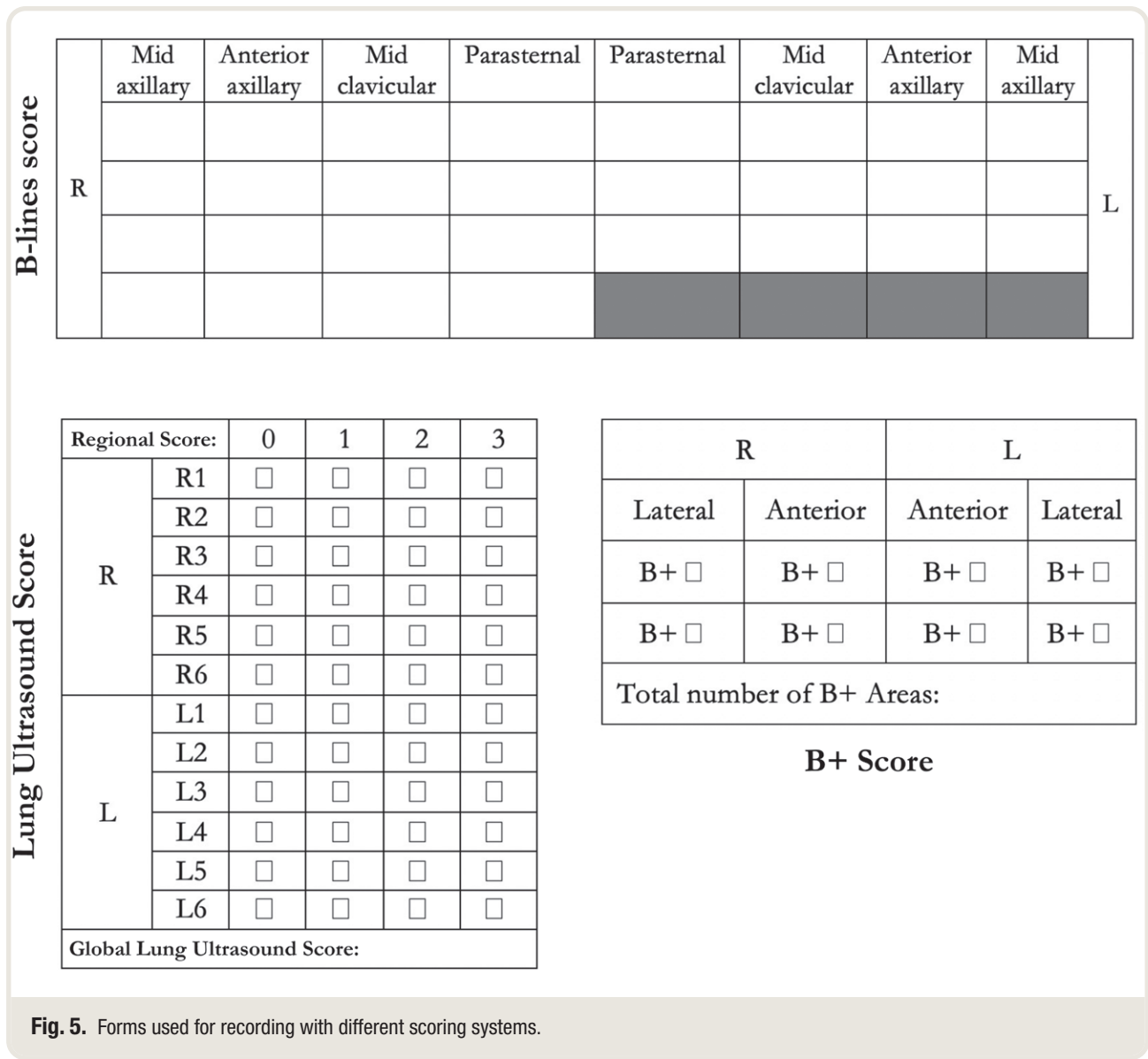


Fig. 5. Forms used for recording with different scoring systems.

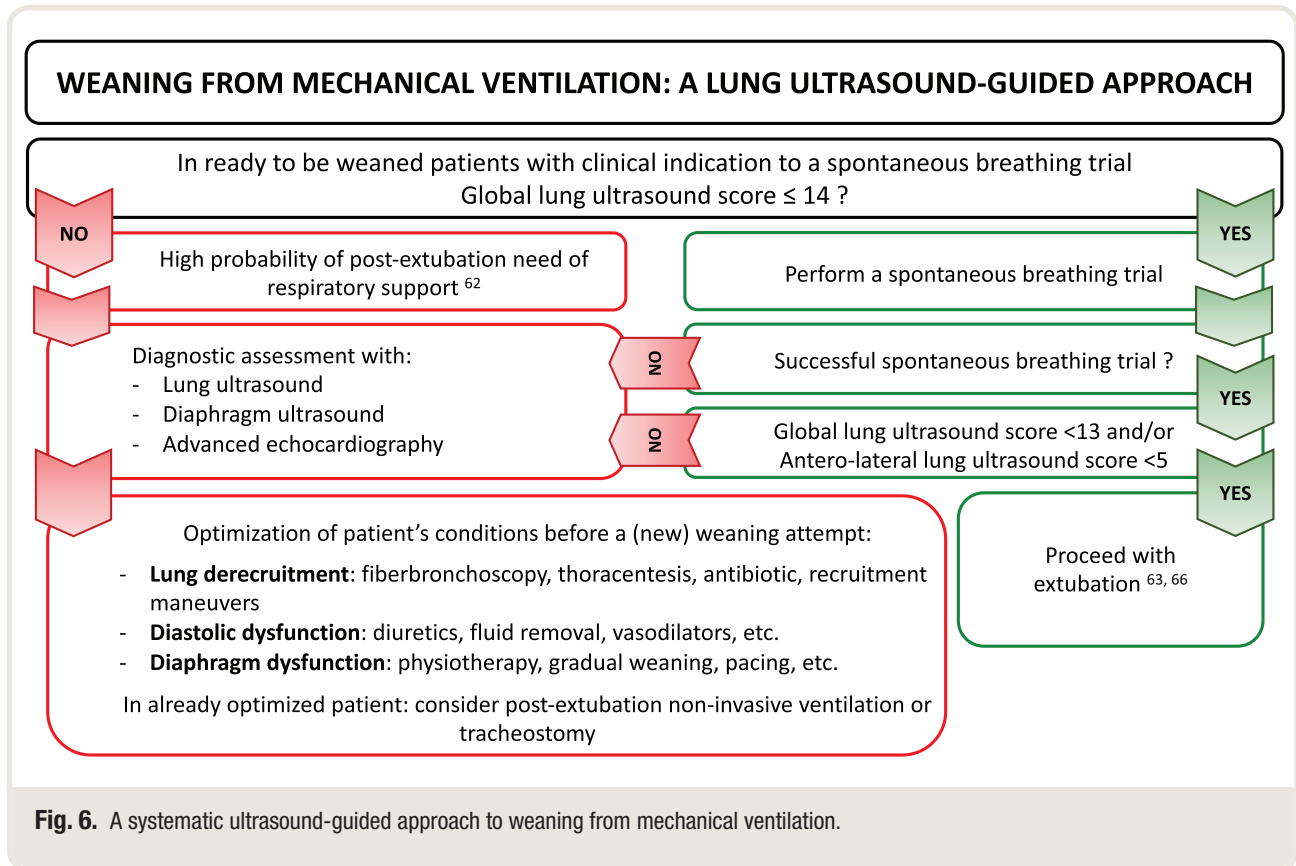
lung sliding with the presence of the lung pulse) accurately identified anesthesia-induced atelectasis, assessed by magnetic resonance imaging.<sup>77</sup>

Although randomized clinical trials have given variable results, it has been suggested that to limit volutrauma and reduce atelectrauma and thus prevent postoperative complications, mechanical ventilation settings must be finely tuned—*i.e.*, based on the use of PEEP, protective lung ventilation, and recruitment maneuvers.<sup>78</sup> Aeration quantified by repeated lung ultrasound serves to monitor the state of the lung during general anesthesia. In a randomized clinical trial, Génereux *et al.*<sup>79</sup> randomized patients to either lung protection or zero PEEP during open gynecological surgery with the primary outcome set as the difference in lung ultrasound score at different perioperative time points. There was significantly less deterioration of lung

aeration during general anesthesia in the protective ventilation group.<sup>79</sup> Moreover, among children under general anesthesia, lung ultrasound-guided recruitment maneuvers significantly reduced the incidence of anesthesia-induced atelectasis.<sup>80</sup>

In postanesthesia care, lung ultrasound accurately detected perioperative pulmonary complications in patients presenting hypoxemia. It was reliable for atelectasis (diagnostic accuracy 97.2%), pneumothorax (diagnostic accuracy 96.7%), and pleural effusion (diagnostic accuracy 95.1%), showing good agreement with thoracic computed tomography scans.<sup>81</sup> There was also good correlation between the lung ultrasound score and the quantitative volumetric data of atelectasis after thoracic surgery.<sup>82</sup>

Consistent with this, lung ultrasound findings and scores in the postanesthesia care unit after major surgery are



**Fig. 6.** A systematic ultrasound-guided approach to weaning from mechanical ventilation.

associated respectively with patient outcome and perioperative pulmonary complications. Zieleskiewicz *et al.*<sup>82</sup> showed that the incidence of perioperative pulmonary complications was higher in patients with alveolar consolidation and pleural effusion, immediately after extubation in the ICU. Furthermore, pleural effusions were associated with intra-hospital mortality, and alveolar consolidation was associated with postoperative mechanical ventilation.<sup>83</sup>

## The Pediatric and Neonatal Critically Ill Patient

### Technical Aspects and Validation with Reference Techniques

Quantitative lung ultrasound is a fairly recent technique in pediatric and neonatal critical care and uses a scoring system very similar to the original one described in the section “The Critically Ill Patient.”<sup>84</sup> The pediatric score has been simplified by the reduction of scanned areas from six to three per hemithorax, creating a single lateral zone on each side without investigating posterior fields, but it shares exactly the same lung ultrasound semiology. Thus, this simplified lung ultrasound score goes from 0 to 18.<sup>20</sup> This choice was made because the pediatric score was originally proposed for neonates and infants who have a smaller chest, making the divisions used for adults difficult. In addition, they are frequently moved from the supine to prone position (and back) as routine

nursing. This makes scanning the posterior lung regions less valuable, at least when the patient has been recently moved. These zones are, however, important for toddlers and older children and also for infants who have been positioned differently after a given time or on purpose for respiratory care reasons. The simplified lung ultrasound score has been validated against several oxygenation measures,<sup>45</sup> such as computerized gray scale analysis<sup>36</sup> and the amount of surfactant available.<sup>85</sup>

The lung ultrasound score is calculated using a high-frequency small linear or a microlinear “golf-stick” probe, given the smaller thorax. However, this must be clearly adapted to patients’ sizes, the amount of subcutaneous tissue, and the equipment available.

The lung ultrasound score computation has high interobserver agreement regardless of the operator’s experience.<sup>20</sup> Moreover, the interpretation of basic lung ultrasound signs on which the score is based is not affected by the use of different probes and loses only slightly when convex probes are used on neonates by novice operators.<sup>86</sup>

The visual interpretation of basic lung ultrasound signs by clinicians and the computerized evaluation have also been compared, and interestingly, the computer analysis was no more accurate than the expert’s.<sup>23</sup> The simplified lung ultrasound score has the same intrinsic limitation as the original and also needs improvement as regards the following: (1) the number and extension of chest zones to be scanned, (2) the size of the tissue-like pattern to be

considered, and (3) the possible modifications to be applied in relation to the patient's greater weight/age.

Like for adult medicine, simpler scores have been proposed, based on the B-lines count or on simple pattern recognition in a whole newborn chest scan. They may be useful respectively to follow up infants with pulmonary edema caused by congenital heart defects<sup>38</sup> or for a first evaluation of respiratory failure early in life,<sup>87</sup> when a more detailed score is not available for lack of training or equipment.

### Surfactants and Bronchopulmonary Dysplasia

The lung ultrasound score has significant accuracy in predicting the need for surfactants in preterm<sup>20</sup> and extremely preterm<sup>88</sup> neonates with respiratory distress syndrome. For this purpose, an ultrasound-guided surfactant policy called ESTHER (Echography-guided Surfactant THERapy) has been proposed.<sup>89</sup> Successive studies reported similar findings,<sup>90–93</sup> and a meta-analysis finally confirmed the accuracy of the lung ultrasound score to guide surfactant replacement.<sup>94</sup>

The score has also been successfully used to guide respiratory care in infants with evolving bronchopulmonary dysplasia (recently also called chronic pulmonary insufficiency of prematurity)<sup>95</sup> and to predict bronchopulmonary dysplasia.<sup>96</sup> Lung ultrasound scores served for monitoring lung aeration and function in extremely preterm infants; when combined with gestational age, they accurately predicted bronchopulmonary dysplasia, starting from the seventh day of life.<sup>97</sup>

### Chronic Diseases

#### Technical Aspects

The availability of lung ultrasound at the bedside, the lack of irradiation, and multiple potential applications for diagnosis and follow-up of chronic disorders make it eminently suitable for internal medicine, cardiology, and rheumatology departments. In the chronic setting, with less time-dependent patients, a more comprehensive approach has been proposed to detect and quantify B-lines,<sup>43</sup> with examination of anterior, lateral, and posterior regions of the chest, scanning every available intercostal space, on both sides, reaching up to 28 scans for the anterolateral chest<sup>98</sup> and up to 72 scans when including posterior fields.<sup>14</sup> Posterior scanning is specially indicated to assess interstitial fibrosis, whereas in all other situations, anterolateral scanning is usually enough, particularly for heart failure.

In chronic settings, too, simplified schemes have been proposed with 8 regions for the anterolateral chest<sup>43</sup> and 14 for the global chest.<sup>99</sup> A quantitative score based on the sum of the visualized B-lines serves to quantify lung congestion, the so-called B-lines score. Usually when there are up to three to four B-lines in a scan, they can be counted one by one. When there are more, they tend to be confluent, and

counting becomes difficult; in this situation, the percentage of the video screen below the pleural line occupied by B-lines should be estimated and then divided by 10 (*i.e.*, if approximately 70% of the screen is occupied by B-lines, it would count as seven B-lines; fig. 4).<sup>100</sup> Phased-array and convex probes are the most widely used, depending on availability, with linear probes usually needed only to visualize the pleural line better. It is easy to learn how to detect B-lines: in a recent trial, an entirely web-based program focused on lung congestion, achieving a high correlation coefficient between each trainee and the expert.<sup>101</sup>

### Validation with Reference Techniques

The B-lines score strongly correlates with the invasive lung gravimetry wet/dry ratio of the lung tissue *in vitro*<sup>25</sup> and correlates well with quantitative computed tomography and extravascular lung water in the acute patient. It also correlated with laboratory (brain natriuretic peptide) and echocardiography findings in chronic heart failure.

### Clinical Applications

When a cross-evaluation was applied to the lung ultrasound score and amino-terminal pro-brain natriuretic peptide in an outpatient heart failure population, a 15-B-line cutoff reliably assessed decompensation, confirmed by amino-terminal pro-brain natriuretic peptide values, chest x-ray films, and a 6-min walking test.<sup>27</sup> This has also been employed to assess prognosis.<sup>102</sup>

Patients with end-stage chronic kidney disease undergoing hemodialysis have a high prevalence of lung congestion because of the increase in extravascular lung water. The number of B-lines before and after treatment can change: B-line resolution seems to occur in real time as fluid is removed from the body<sup>24,35</sup> and is also related to weight loss and smaller vena cava diameter after dialysis.<sup>26</sup> In these patients, the decrease in the number of B-lines correlates with the increase of thoracic impedance, indicative of a drop in lung water content.<sup>29</sup> Thus, the B-lines score can safely guide a strategy for dry weight reduction,<sup>103</sup> to assess pulmonary congestion<sup>29</sup> and prevent fluid overload.<sup>104</sup> The score is also associated with clinical outcome in end-stage renal disease patients with cardiovascular disease.<sup>105</sup>

Lung ultrasound can detect interstitial lung diseases in a variety of conditions. Many articles report good correlation with computed tomography, especially in patients with connective tissue disease.<sup>14</sup> The literature shows considerable differences in probes, scanning techniques, scoring systems, and interpretation.<sup>106</sup> However, overall there is evidence that lung ultrasound helps in the diagnosis of interstitial lung diseases, and the number of B-lines correlates well with computed tomography,<sup>33,80</sup> pulmonary function tests, and disease severity scales.<sup>30,107</sup> Lung ultrasound offers 100% sensitivity and negative predictive value in both early and advanced systemic sclerosis, making it a useful screening

tool for interstitial lung disease. The B-lines score correlates with the radiological score and can predict deterioration in interstitial lung disease.<sup>34</sup>

### Automation and Future Prospects

Computer-aided diagnosis is rapidly becoming part of lung ultrasound equipment. The computer output is used as a “second opinion,” assisting physicians in image interpretation. The computer algorithm generally consists of several steps, which may include image processing, image feature analysis, and data classification using tools such as artificial neural networks.<sup>108</sup> With lung ultrasound, objective diagnostic assistance could facilitate the interpretation of images. This has the potential to be advantageous in terms of better interobserver agreement, faster data analysis, and applicability to large sets of data.<sup>42</sup>

Some seminal studies have examined the feasibility of computer-aided diagnosis for reliable quantification of B-lines in a sample set of lung ultrasound clips<sup>39,109</sup> and provided valuable insight on the clinical meaning of B-lines being strongly correlated with extravascular lung water but weakly with physical density,<sup>39</sup> in contrast to computed tomography (fig. 7).

A soft computing-based B-line analysis was initially developed for automated quantitative classification of the severity of pulmonary interstitial syndrome<sup>110</sup> but could not differentiate pulmonary edema and fibrosis. A MATLAB (MathWorks, USA)-based algorithm was then developed to process image loops after ultrasound acquisition in a region of interest defined by the user.<sup>111</sup> That early study confirmed that B-mode images vary considerably in B-line features such as number, brightness, intensity, and persistence during the respiratory cycle, indicating how an algorithm-based approach was able to process considerably more data than was manually possible.

In 2015, a histogram-based software of textural features from echo signals was developed. In spontaneously

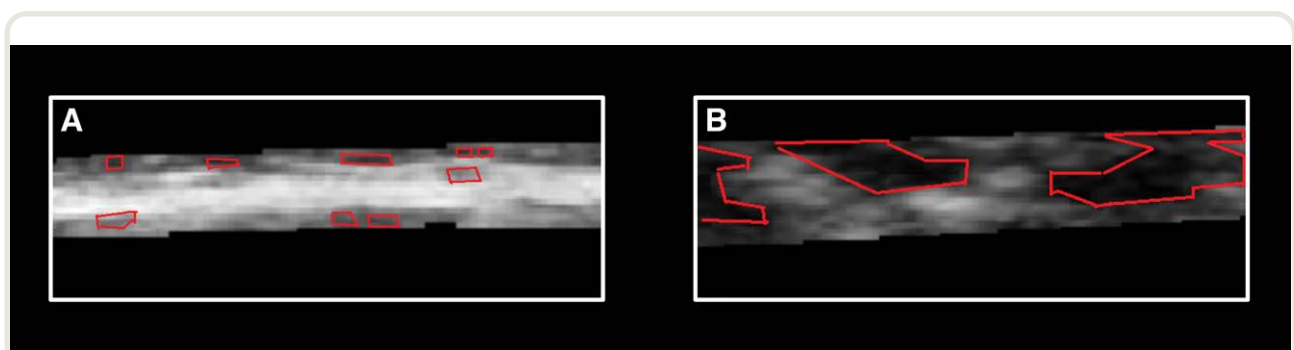
breathing patients, this method was considerably more accurate than either chest x-ray film or visual ultrasonography in the diagnosis of community-acquired pneumonia, independently of size and distance from the pleural line, also compared with computed tomography.<sup>40</sup> In mechanically ventilated patients, this analysis provided better diagnostic accuracy for detecting increased extravascular lung water than visual scoring, also compared to the EV1000 clinical platform.<sup>41</sup> In 2018, an algorithm to detect, characterize, and count B-lines was presented.<sup>112</sup> It discriminated healthy from unhealthy lung scans. In 2019, a further algorithm was developed for automatic detection and quantification of B-lines.<sup>42</sup> That study demonstrated that a computer-aided scoring algorithm of the percentage of the pleural line affected by B-lines gave the best interobserver agreement among various scoring systems. Finally, in 2020, a new algorithm for specific analysis of the pleural line and the immediate subpleural space, based on the gray-level co-occurrence matrix with a second-order statistical method of texture analysis, showed the potential for helping in the differential diagnosis of pulmonary edemas.<sup>113</sup>

These studies illustrate an initial step toward the goal of developing an algorithm to compute an automatic, operator-independent score for B-lines. The added value of computer-aided diagnosis lies in the use of a pattern recognition based on an artificial neural network to create a new decision support system tool for processing lung ultrasound images.

### Limitations

Every ultrasound examination is operator-dependent, and adequate training is mandatory. The learning curve for lung ultrasound is steep, so even relatively short training can achieve high concordance between expert and nonexpert operators.<sup>52,101</sup> Automation may further improve this.

The penetration of ultrasound to the pleura is prevented by the interposition of a chest drain, dressing and air,



**Fig. 7.** Automation in lung ultrasound assessment. (A) A local zoom of a pleural line from an acute pulmonary edema patient. The area shows small regions with uniform *dark gray* intensity, resulting in a “low correlation.” (B) A local zoom of an acute respiratory distress syndrome (ARDS) pleural line area shows large regions with uniform *dark gray* intensity, resulting in a “high correlation.”<sup>41</sup>

subcutaneous emphysema, and wounds or burns preventing direct contact with the skin. Moreover, lung ultrasound assessment takes only a few minutes and is normally part of the clinical assessment. Finally, it does improve patient management, in terms of time to diagnosis and time to advanced examinations.<sup>5</sup>

## Conclusions

Lung ultrasound is a powerful tool to integrate the clinical assessment of the lung in multiple fields. Different scoring systems have now been validated to improve the use of lung ultrasound not only as a diagnostic tool but also for monitoring lung aeration. Each approach responds to different clinical needs and should be applied in the appropriate clinical contexts. Computer-aided technology has the potential to make quantitative lung ultrasound assessment faster and more reliable, particularly in nonexpert hands, facilitating the further spread of this technique.

## Research Support

Support was provided solely from institutional and/or departmental sources.

## Competing Interests

Dr. Mojoli received fees for lectures from GE Healthcare (Boston, Massachusetts), Hamilton Medical (Bonaduz, Switzerland), and SEDA Società Per Azioni (Trezzano sul Naviglio, Italy), outside the current work. A research agreement is active between University of Pavia and Hamilton Medical. Dr. Mongodi received fees for lectures from GE Healthcare, outside the current work. Dr. De Luca received travel grants and lecture fees from Philips Healthcare (Amsterdam, The Netherlands) and research assistance from GE Healthcare, outside the current work. Dr. Gargani received consultancy fees from GE Healthcare and had financial relationships with Philips Healthcare and Caption Health (Brisbane, California), outside the current work. The other authors declare no competing interests.

## Correspondence

Address correspondence to Dr. Mongodi: Rianimazione I, Fondazione IRCCS Policlinico S. Matteo, Viale Golgi 19, Pavia, Italy. [silvia.mongodi@libero.it](mailto:silvia.mongodi@libero.it) or [s.mongodi@smatteo.pv.it](mailto:s.mongodi@smatteo.pv.it). ANESTHESIOLOGY's articles are made freely accessible to all readers on [www.anesthesiology.org](http://www.anesthesiology.org), for personal use only, 6 months from the cover date of the issue.

## References

- Volpicelli G, Elbarbary M, Blaivas M, Lichtenstein DA, Mathis G, Kirkpatrick AW, Melniker L, Gargani L, Noble VE, Via G, Dean A, Tsung JW, Soldati G, Copetti R, Bouhemad B, Reissig A, Agricola E, Rouby JJ, Arbelot C, Liteplo A, Sargsyan A, Silva F, Hoppmann R, Breikreutz R, Seibel A, Neri L, Storti E, Petrovic T; International Liaison Committee on Lung Ultrasound (ILC-LUS) for International Consensus Conference on Lung Ultrasound (ICC-LUS): International evidence-based recommendations for point-of-care lung ultrasound. *Intensive Care Med* 2012; 38:577–91
- Mojoli F, Bouhemad B, Mongodi S, Lichtenstein D: Lung ultrasound for critically ill patients. *Am J Respir Crit Care Med* 2019; 199:701–14
- Mayo PH, Copetti R, Feller-Kopman D, Mathis G, Maury E, Mongodi S, Mojoli F, Volpicelli G, Zanobetti M: Thoracic ultrasonography: A narrative review. *Intensive Care Med* 2019; 45:1200–11
- Bouhemad B, Mongodi S, Via G, Rouquette I: Ultrasound for “lung monitoring” of ventilated patients. *ANESTHESIOLOGY* 2015; 122:437–47
- Laursen CB, Sloth E, Lassen AT, Christensen RD, Lambrechtsen J, Madsen PH, Henriksen DP, Davidsen JR, Rasmussen F: Point-of-care ultrasonography in patients admitted with respiratory symptoms: A single-blind, randomised controlled trial. *Lancet Respir Med* 2014; 2:638–46
- Riviello ED, Kiviri W, Twagirumugabe T, Mueller A, Banner-Goodspeed VM, Officer L, Novack V, Mutumwinka M, Talmor DS, Fowler RA: Hospital incidence and outcomes of the acute respiratory distress syndrome using the Kigali modification of the Berlin definition. *Am J Respir Crit Care Med* 2016; 193:52–9
- Xirouchaki N, Kondili E, Prinianakis G, Malliotakis P, Georgopoulos D: Impact of lung ultrasound on clinical decision making in critically ill patients. *Intensive Care Med* 2014; 40:57–65
- Brogi E, Bignami E, Sidoti A, Shawar M, Gargani L, Vetrugno L, Volpicelli G, Forfori F: Could the use of bedside lung ultrasound reduce the number of chest x-rays in the intensive care unit? *Cardiovasc Ultrasound* 2017; 15:23
- Mongodi S, Orlando A, Arisi E, Tavazzi G, Santangelo E, Caneva L, Pozzi M, Pariani E, Bettini G, Maggio G, Perlini S, Preda L, Iotti GA, Mojoli F: Lung ultrasound in patients with acute respiratory failure reduces conventional imaging and health care provider exposure to COVID-19. *Ultrasound Med Biol* 2020; 46:2090–3
- Picano E, Frassi F, Agricola E, Gligorova S, Gargani L, Mottola G: Ultrasound lung comets: A clinically useful sign of extravascular lung water. *J Am Soc Echocardiogr* 2006; 19:356–63
- Gheorghide M, Follath F, Ponikowski P, Barsuk JH, Blair JE, Cleland JG, Dickstein K, Drazner MH, Fonarow GC, Jaarsma T, Jondeau G, Sendon JL, Mebazaa A, Metra M, Nieminen M, Pang PS, Seferovic P, Stevenson LW, van Veldhuisen DJ, Zannad F, Anker SD, Rhodes A, McMurray JJ, Filippatos G; European Society of Cardiology; European Society of Intensive Care Medicine: Assessing and grading congestion in acute heart failure: A scientific statement

- from the acute heart failure committee of the heart failure association of the European Society of Cardiology and endorsed by the European Society of Intensive Care Medicine. *Eur J Heart Fail* 2010; 12:423–33
12. Lancellotti P, Price S, Edvardsen T, Cosyns B, Neskovic AN, Dulgheru R, Flachskampf FA, Hassager C, Pasquet A, Gargani L, Galderisi M, Cardim N, Haugaa KH, Ancion A, Zamorano JL, Donal E, Bueno H, Habib G: The use of echocardiography in acute cardiovascular care: Recommendations of the European Association of Cardiovascular Imaging and the Acute Cardiovascular Care Association. *Eur Heart J Cardiovasc Imaging* 2015; 16:119–46
  13. Torino C, Gargani L, Sicari R, Letachowicz K, Ekart R, Fliser D, Covic A, Siamopoulos K, Stavroulopoulos A, Massy ZA, Fiaccadori E, Caiazza A, Bachelet T, Slotki I, Martinez-Castelao A, Coudert-Krier MJ, Rossignol P, Gueler F, Hannedouche T, Panichi V, Wiecek A, Pontoriero G, Sarafidis P, Klinger M, Hojs R, Seiler-Mussler S, Lizzi F, Siriopol D, Balafa O, Shavit L, Tripepi R, Mallamaci F, Tripepi G, Picano E, London GM, Zoccali C: The agreement between auscultation and lung ultrasound in hemodialysis patients: The LUST study. *Clin J Am Soc Nephrol* 2016; 11:2005–11
  14. Wang Y, Gargani L, Barskova T, Furst DE, Cerinic MM: Usefulness of lung ultrasound B-lines in connective tissue disease-associated interstitial lung disease: A literature review. *Arthritis Res Ther* 2017; 19:206
  15. Soldati G, Inchingolo R, Smargiassi A, Sher S, Nenna R, Inchingolo CD, Valente S: *Ex vivo* lung sonography: Morphologic-ultrasound relationship. *Ultrasound Med Biol* 2012; 38:1169–79
  16. Via G, Lichtenstein D, Mojoli F, Rodi G, Neri L, Storti E, Klersy C, Iotti G, Braschi A: Whole lung lavage: A unique model for ultrasound assessment of lung aeration changes. *Intensive Care Med* 2010; 36:999–1007
  17. Bouhemad B, Liu ZH, Arbelot C, Zhang M, Ferarri F, Le-Guen M, Girard M, Lu Q, Rouby JJ: Ultrasound assessment of antibiotic-induced pulmonary re-aeration in ventilator-associated pneumonia. *Crit Care Med* 2010; 38:84–92
  18. Bouhemad B, Brisson H, Le-Guen M, Arbelot C, Lu Q, Rouby JJ: Bedside ultrasound assessment of positive end-expiratory pressure-induced lung recruitment. *Am J Respir Crit Care Med* 2011; 183:341–7
  19. Zhao Z, Jiang L, Xi X, Jiang Q, Zhu B, Wang M, Xing J, Zhang D: Prognostic value of extravascular lung water assessed with lung ultrasound score by chest sonography in patients with acute respiratory distress syndrome. *BMC Pulm Med* 2015; 15:98
  20. Brat R, Yousef N, Klifa R, Reynaud S, Shankar Aguilera S, De Luca D: Lung ultrasonography score to evaluate oxygenation and surfactant need in neonates treated with continuous positive airway pressure. *JAMA Pediatr* 2015; 169:e151797
  21. Caltabeloti F, Monsel A, Arbelot C, Brisson H, Lu Q, Gu WJ, Zhou GJ, Auler JO, Rouby JJ: Early fluid loading in acute respiratory distress syndrome with septic shock deteriorates lung aeration without impairing arterial oxygenation: A lung ultrasound observational study. *Crit Care* 2014; 18:R91
  22. Chiumello D, Mongodi S, Algieri I, Vergani GL, Orlando A, Via G, Crimella F, Cressoni M, Mojoli F: Assessment of lung aeration and recruitment by CT scan and ultrasound in acute respiratory distress syndrome patients. *Crit Care Med* 2018; 46:1761–8
  23. Raimondi F, Migliaro F, Verdoliva L, Gragnaniello D, Poggi G, Kosova R, Sansone C, Vallone G, Capasso L: Visual assessment *versus* computer-assisted gray scale analysis in the ultrasound evaluation of neonatal respiratory status. *PLoS One* 2018; 13:e0202397
  24. Noble VE, Murray AF, Capp R, Sylvia-Reardon MH, Steele DJR, Liteplo A: Ultrasound assessment for extravascular lung water in patients undergoing hemodialysis: Time course for resolution. *Chest* 2009; 135:1433–9
  25. Jambrik Z, Gargani L, Adamicza A, Kaszaki J, Varga A, Forster T, Boros M, Picano E: B-lines quantify the lung water content: A lung ultrasound *versus* lung gravimetry study in acute lung injury. *Ultrasound Med Biol* 2010; 36:2004–10
  26. Trezzi M, Torzillo D, Ceriani E, Costantino G, Caruso S, Damavandi PT, Genderini A, Cicardi M, Montano N, Cogliati C: Lung ultrasonography for the assessment of rapid extravascular water variation: Evidence from hemodialysis patients. *Intern Emerg Med* 2013; 8:409–15
  27. Miglioranza MH, Gargani L, Sant'Anna RT, Rover MM, Martins VM, Mantovani A, Weber C, Moraes MA, Feldman CJ, Kalil RA, Sicari R, Picano E, Leiria TL: Lung ultrasound for the evaluation of pulmonary congestion in outpatients: A comparison with clinical assessment, natriuretic peptides, and echocardiography. *JACC Cardiovasc Imaging* 2013; 6:1141–51
  28. Baldi G, Gargani L, Abramo A, D'Errico L, Caramella D, Picano E, Giunta F, Forfori F: Lung water assessment by lung ultrasonography in intensive care: A pilot study. *Intensive Care Med* 2013; 39:74–84
  29. Donadio C, Bozzoli L, Colombini E, Pisanu G, Ricchiuti G, Picano E, Gargani L: Effective and timely evaluation of pulmonary congestion: Qualitative comparison between lung ultrasound and thoracic bioelectrical impedance in maintenance hemodialysis patients. *Medicine (Baltimore)* 2015; 94:e473
  30. Gigante A, Rossi Fanelli F, Lucci S, Barilaro G, Quarta S, Barbano B, Giovannetti A, Amoroso A, Rosato E: Lung ultrasound in systemic sclerosis: Correlation with high-resolution computed tomography, pulmonary function tests and clinical variables of disease. *Intern Emerg Med* 2016; 11:213–7
  31. Anile A, Russo J, Castiglione G, Volpicelli G: A simplified lung ultrasound approach to detect increased

- extravascular lung water in critically ill patients. *Crit Ultrasound J* 2017; 9:13
32. Buessler A, Chouihed T, Duarte K, Bassand A, Huot-Marchand M, Gottwalles Y, Pénine A, André E, Nace L, Jaeger D, Kobayashi M, Coiro S, Rossignol P, Girerd N: Accuracy of several lung ultrasound methods for the diagnosis of acute heart failure in the ED: A multi-center prospective study. *Chest* 2020; 157:99–110
  33. Man MA, Dantes E, Domokos Hancu B, Bondor CI, Ruscovan A, Parau A, Motoc NS, Marc M: Correlation between transthoracic lung ultrasound score and HRCT features in patients with interstitial lung diseases. *J Clin Med* 2019; 8:1199
  34. Gasperini ML, Gigante A, Iacolare A, Pellicano C, Lucci S, Rosato E: The predictive role of lung ultrasound in progression of scleroderma interstitial lung disease. *Clin Rheumatol* 2020; 39:119–23
  35. Mallamaci F, Benedetto FA, Tripepi R, Rastelli S, Castellino P, Tripepi G, Picano E, Zoccali C: Detection of pulmonary congestion by chest ultrasound in dialysis patients. *JACC Cardiovasc Imaging* 2010; 3:586–94
  36. Li H, Li YD, Zhu WW, Kong LY, Ye XG, Cai QZ, Sun LL, Lu XZ: A simplified ultrasound comet tail grading scoring to assess pulmonary congestion in patients with heart failure. *Biomed Res Int* 2018; 2018:8474839
  37. Volpicelli G, Skurzak S, Boero E, Carpinteri G, Tengattini M, Stefanone V, Luberto L, Anile A, Cerutti E, Radeschi G, Frascisco MF: Lung ultrasound predicts well extravascular lung water but is of limited usefulness in the prediction of wedge pressure. *ANESTHESIOLOGY* 2014; 121:320–7
  38. Del Rey Hurtado de Mendoza B, Sánchez-de-Toledo J, Bobillo Perez S, Girona M, Balaguer Gargallo M, Rodríguez-Fanjul J: Lung ultrasound to assess the etiology of persistent pulmonary hypertension of the newborn (LUPPHYN study): A pilot study. *Neonatology* 2019; 116:140–6
  39. Corradi F, Ball L, Brusasco C, Riccio AM, Baroffio M, Bovio G, Pelosi P, Brusasco V: Assessment of extravascular lung water by quantitative ultrasound and CT in isolated bovine lung. *Respir Physiol Neurobiol* 2013; 187:244–9
  40. Corradi F, Brusasco C, Garlaschi A, Paparo F, Ball L, Santori G, Pelosi P, Altomonte F, Vezzani A, Brusasco V: Quantitative analysis of lung ultrasonography for the detection of community-acquired pneumonia: A pilot study. *Biomed Res Int* 2015; 2015:868707
  41. Corradi F, Brusasco C, Vezzani A, Santori G, Manca T, Ball L, Nicolini F, Gherli T, Brusasco V: Computer-aided quantitative ultrasonography for detection of pulmonary edema in mechanically ventilated cardiac surgery patients. *Chest* 2016; 150:640–51
  42. Brusasco C, Santori G, Bruzzo E, Trò R, Robba C, Tavazzi G, Guarracino F, Forfori F, Boccacci P, Corradi F: Quantitative lung ultrasonography: A putative new algorithm for automatic detection and quantification of B-lines. *Crit Care* 2019; 23:288
  43. Gargani L, Volpicelli G: How I do it: Lung ultrasound. *Cardiovasc Ultrasound* 2014; 12:25
  44. Volpicelli G, Melniker LA, Cardinale L, Lamorte A, Frascisco MF: Lung ultrasound in diagnosing and monitoring pulmonary interstitial fluid. *Radiol Med* 2013; 118:196–205
  45. Volpicelli G, Noble VE, Liteplo A, Cardinale L: Decreased sensitivity of lung ultrasound limited to the anterior chest in emergency department diagnosis of cardiogenic pulmonary edema: A retrospective analysis. *Crit Ultrasound J* 2010; 2:47–52
  46. Volpicelli G, Caramello V, Cardinale L, Mussa A, Bar F, Frascisco MF: Bedside ultrasound of the lung for the monitoring of acute decompensated heart failure. *Am J Emerg Med* 2008; 26:585–91
  47. Arora S, Singh PM, Goudra BG, Sinha AC: Changing trends of hemodynamic monitoring in ICU—From invasive to non-invasive methods: Are we there yet? *Int J Crit Illn Inj Sci* 2014; 4:168–77
  48. Ross DW, Abbasi MM, Jhaveri KD, Sachdeva M, Miller I, Barnett R, Narasimhan M, Mayo P, Merzkani M, Mathew AT: Lung ultrasonography in end-stage renal disease: Moving from evidence to practice: A narrative review. *Clin Kidney J* 2018; 11:172–8
  49. Liu ZP, Zhang Y, Bian H, He XR, Zhou YJ, Wang LJ, Ding N: Clinical application of rapid B-line score with lung ultrasonography in differentiating between pulmonary infection and pulmonary infection with acute left ventricular heart failure. *Am J Emerg Med* 2016; 34:278–81
  50. Santos TM, Franci D, Coutinho CM, Ribeiro DL, Schweller M, Matos-Souza JR, Carvalho-Filho MA: A simplified ultrasound-based edema score to assess lung injury and clinical severity in septic patients. *Am J Emerg Med* 2013; 31:1656–60
  51. Mongodi S, Bouhemad B, Orlando A, Stella A, Tavazzi G, Via G, Iotti GA, Braschi A, Mojoli F: Modified lung ultrasound score for assessing and monitoring pulmonary aeration. *Ultraschall Med* 2017; 38:530–7
  52. Rouby JJ, Arbelot C, Gao Y, Zhang M, Lv J, An Y, Chunyao W, Bin D, Valente Barbas CS, Dexheimer Neto FL, Prior Caltabeloti F, Lima E, Cebea A, Perbet S, Constantin JM; APECHO Study Group: Training for lung ultrasound score measurement in critically ill patients. *Am J Respir Crit Care Med* 2018; 198:398–401
  53. Zieleskiewicz L, Markarian T, Lopez A, Taguet C, Mohammedi N, Boucekine M, Baumstarck K, Besch G, Mathon G, Duclos G, Bouvet L, Michelet P, Allaouchiche B, Chaumôtre K, Di Bisceglie M, Leone M; AZUREA Network: Comparative study of lung ultrasound and chest computed tomography scan in

- the assessment of severity of confirmed COVID-19 pneumonia. *Intensive Care Med* 2020; 46:1707–13
54. Mongodi S, Pozzi M, Orlando A, Bouhemad B, Stella A, Tavazzi G, Via G, Iotti GA, Mojoli F: Lung ultrasound for daily monitoring of ARDS patients on extracorporeal membrane oxygenation: Preliminary experience. *Intensive Care Med* 2018; 44:123–4
  55. Lu X, Arbelot C, Schreiber A, Langeron O, Monsel A, Lu Q: Ultrasound assessment of lung aeration in subjects supported by venovenous extracorporeal membrane oxygenation. *Respir Care* 2019; 64:1478–87
  56. Constantin JM, Jabaudon M, Lefrant JY, Jaber S, Quenot JP, Langeron O, Ferrandière M, Grelon F, Seguin P, Ichai C, Veber B, Souweine B, Uberti T, Lasocki S, Legay F, Leone M, Eisenmann N, Dahyot-Fizelier C, Dupont H, Asehnoune K, Sossou A, Chanques G, Muller L, Bazin JE, Monsel A, Borao L, Garcier JM, Rouby JJ, Pereira B, Futier E; AZUREA Network: Personalised mechanical ventilation tailored to lung morphology *versus* low positive end-expiratory pressure for patients with acute respiratory distress syndrome in France (the LIVE study): A multicentre, single-blind, randomised controlled trial. *Lancet Respir Med* 2019; 7:870–80
  57. Mongodi S, Santangelo E, Bouhemad B, Vaschetto R, Mojoli F: Personalised mechanical ventilation in acute respiratory distress syndrome: The right idea with the wrong tools? *Lancet Respir Med* 2019; 7:e38
  58. Prat G, Guinard S, Bizien N, Nowak E, Tonnelier JM, Alavi Z, Renault A, Boles JM, L'Her E: Can lung ultrasonography predict prone positioning response in acute respiratory distress syndrome patients? *J Crit Care* 2016; 32:36–41
  59. Haddam M, Zieleskiewicz L, Perbet S, Baldovini A, Guervilly C, Arbelot C, Noel A, Vigne C, Hammad E, Antonini F, Lehingue S, Peytel E, Lu Q, Bouhemad B, Golmard JL, Langeron O, Martin C, Muller L, Rouby JJ, Constantin JM, Papazian L, Leone M; CAR'Echo Collaborative Network; AzuRea Collaborative Network: Lung ultrasonography for assessment of oxygenation response to prone position ventilation in ARDS. *Intensive Care Med* 2016; 42:1546–56
  60. Wang XT, Ding X, Zhang HM, Chen H, Su LX, Liu DW; Chinese Critical Ultrasound Study Group (CCUSG): Lung ultrasound can be used to predict the potential of prone positioning and assess prognosis in patients with acute respiratory distress syndrome. *Crit Care* 2016; 20:385
  61. Huang D, Ma H, Xiao Z, Blaivas M, Chen Y, Wen J, Guo W, Liang J, Liao X, Wang Z, Li H, Li J, Chao Y, Wang XT, Wu Y, Qin T, Su K, Wang S, Tan N: Diagnostic value of cardiopulmonary ultrasound in elderly patients with acute respiratory distress syndrome. *BMC Pulm Med* 2018; 18:136
  62. Dransart-Rayé O, Roldi E, Zieleskiewicz L, Guinot PG, Mojoli F, Mongodi S, Bouhemad B: Lung ultrasound for early diagnosis of postoperative need for ventilatory support: A prospective observational study. *Anaesthesia* 2020; 75:202–9
  63. Soummer A, Perbet S, Brisson H, Arbelot C, Constantin JM, Lu Q, Rouby JJ; Lung Ultrasound Study Group: Ultrasound assessment of lung aeration loss during a successful weaning trial predicts postextubation distress. *Crit Care Med* 2012; 40:2064–72
  64. Silva S, Ait Aissa D, Cocquet P, Hoarau L, Ruiz J, Ferre F, Rousset D, Mora M, Mari A, Fourcade O, Riu B, Jaber S, Bataille B: Combined thoracic ultrasound assessment during a successful weaning trial predicts postextubation distress. *ANESTHESIOLOGY* 2017; 127:666–74
  65. Ferré A, Guillot M, Lichtenstein D, Mezière G, Richard C, Teboul JL, Monnet X: Lung ultrasound allows the diagnosis of weaning-induced pulmonary oedema. *Intensive Care Med* 2019; 45:601–8
  66. Bouhemad B, Mojoli F, Nowobilski N, Hussain A, Rouquette I, Guinot PG, Mongodi S: Use of combined cardiac and lung ultrasound to predict weaning failure in elderly, high-risk cardiac patients: A pilot study. *Intensive Care Med* 2020; 46:475–84
  67. Lichter Y, Topilsky Y, Taieb P, Banai A, Hochstadt A, Merdler I, Gal Oz A, Vine J, Goren O, Cohen B, Sapir O, Granot Y, Mann T, Friedman S, Angel Y, Adi N, Laufer-Perl M, Ingbir M, Arbel Y, Matot I, Szekely Y: Lung ultrasound predicts clinical course and outcomes in COVID-19 patients. *Intensive Care Med* 2020; 46:1873–83
  68. Güney T, Gürsel G, Özdemir U, Tekin Ö, Çimen M, Mamadova A, Karaaslan N: Are pocket sized ultrasound devices sufficient in the evaluation of lung ultrasound patterns and aeration scoring in pulmonary ICU patients? *J Clin Monit Comput* 2020 [Epub ahead of print]
  69. Bennett D, De Vita E, Mezzasalma F, Lanzarone N, Cameli P, Bianchi F, Perillo F, Bargagli E, Mazzei MA, Volterrani L, Scolletta S, Valente S, Franchi F, Frediani B, Sestini P: Portable pocket-sized ultrasound scanner for the evaluation of lung involvement in coronavirus disease 2019 patients. *Ultrasound Med Biol* 2021; 47:19–24
  70. Brueckmann B, Villa-Urbe JL, Bateman BT, Grosse-Sundrup M, Hess DR, Schlett CL, Eikermann M: Development and validation of a score for prediction of postoperative respiratory complications. *ANESTHESIOLOGY* 2013; 118:1276–85
  71. Futier E, Constantin JM, Paugam-Burtz C, Pascal J, Eurin M, Neuschwander A, Marret E, Beaussier M, Gutton C, Lefrant JY, Allaouchiche B, Verzilli D, Leone M, De Jong A, Bazin JE, Pereira B, Jaber S; IMPROVE Study Group: A trial of intraoperative low-tidal-volume ventilation in abdominal surgery. *N Engl J Med* 2013; 369:428–37
  72. Szabó M, Bozó A, Darvas K, Soós S, Ózse M, Iványi ZD: The role of ultrasonographic lung aeration score

- in the prediction of postoperative pulmonary complications: An observational study. *BMC Anesthesiol* 2021; 21:19
73. Ford JW, Heiberg J, Brennan AP, Royse CF, Canty DJ, El-Ansary D, Royse AG: A pilot assessment of 3 point-of-care strategies for diagnosis of perioperative lung pathology. *Anesth Analg* 2017; 124:734–42
  74. Touw HR, Parlevliet KL, Beerepoot M, Schober P, Vonk A, Twisk JW, Elbers PW, Boer C, Tuinman PR: Lung ultrasound compared with chest X-ray in diagnosing postoperative pulmonary complications following cardiothoracic surgery: A prospective observational study. *Anaesthesia* 2018; 73:946–54
  75. Miskovic A, Lumb AB: Postoperative pulmonary complications. *Br J Anaesth* 2017; 118:317–34
  76. Monastesse A, Girard F, Massicotte N, Chartrand-Lefebvre C, Girard M: Lung ultrasonography for the assessment of perioperative atelectasis: A pilot feasibility study. *Anesth Analg* 2017; 124:494–504
  77. Acosta CM, Maidana GA, Jacovitti D, Belaunzarán A, Cereceda S, Rae E, Molina A, Gonorazky S, Bohm SH, Tusman G: Accuracy of transthoracic lung ultrasound for diagnosing anesthesia-induced atelectasis in children. *ANESTHESIOLOGY* 2014; 120:1370–9
  78. Futier E, Marret E, Jaber S: Perioperative positive pressure ventilation: An integrated approach to improve pulmonary care. *ANESTHESIOLOGY* 2014; 121:400–8
  79. Génèreux V, Chassé M, Girard F, Massicotte N, Chartrand-Lefebvre C, Girard M: Effects of positive end-expiratory pressure/recruitment manoeuvres compared with zero end-expiratory pressure on atelectasis during open gynaecological surgery as assessed by ultrasonography: A randomised controlled trial. *Br J Anaesth* 2020; 124:101–9
  80. Song G, Bae SC, Lee YH: Diagnostic accuracy of lung ultrasound for interstitial lung disease in patients with connective tissue diseases: A meta-analysis. *Clin Exp Rheumatol* 2016; 34:11–6
  81. Xie C, Sun K, You Y, Ming Y, Yu X, Yu L, Huang J, Yan M: Feasibility and efficacy of lung ultrasound to investigate pulmonary complications in patients who developed postoperative hypoxaemia: A prospective study. *BMC Anesthesiol* 2020; 20:220
  82. Yu X, Zhai Z, Zhao Y, Zhu Z, Tong J, Yan J, Ouyang W: Performance of lung ultrasound in detecting peri-operative atelectasis after general anesthesia. *Ultrasound Med Biol* 2016; 42:2775–84
  83. Zieleskiewicz L, Papinko M, Lopez A, Baldovini A, Fiocchi D, Meresse Z, Boussuges A, Thomas PA, Berdah S, Creagh-Brown B, Bouhemad B, Futier E, Resseguier N, Antonini F, Duclos G, Leone M: Lung ultrasound findings in the postanesthesia care unit are associated with outcome after major surgery: A prospective observational study in a high-risk cohort. *Anesth Analg* 2021; 132:172–81
  84. Raimondi F, Yousef N, Migliaro F, Capasso L, De Luca D: Point-of-care lung ultrasound in neonatology: Classification into descriptive and functional applications. *Pediatr Res* 2018 [Epub ahead of print]
  85. Autilio C, Echaide M, Benachi A, Marfaing-Koka A, Capoluongo ED, Pérez-Gil J, De Luca D: A noninvasive surfactant adsorption test predicting the need for surfactant therapy in preterm infants treated with continuous positive airway pressure. *J Pediatr* 2017; 182:66–73.e1
  86. Gomond-Le Goff C, Vivalda L, Foligno S, Loi B, Yousef N, De Luca D: Effect of different probes and expertise on the interpretation reliability of point-of-care lung ultrasound. *Chest* 2020; 157:924–31
  87. Raimondi F, Migliaro F, Sodano A, Umbaldo A, Romano A, Vallone G, Capasso L: Can neonatal lung ultrasound monitor fluid clearance and predict the need of respiratory support? *Crit Care* 2012; 16:R220
  88. De Martino L, Yousef N, Ben-Ammar R, Raimondi F, Shankar-Aguilera S, De Luca D: Lung ultrasound score predicts surfactant need in extremely preterm neonates. *Pediatrics* 2018; 142:e20180463
  89. Raschetti R, Yousef N, Vigo G, Marseglia G, Centorrino R, Ben-Ammar R, Shankar-Aguilera S, De Luca D: Echography-guided surfactant therapy to improve timeliness of surfactant replacement: A quality improvement project. *J Pediatr* 2019; 212:137–143.e1
  90. Pang H, Zhang B, Shi J, Zang J, Qiu L: Diagnostic value of lung ultrasound in evaluating the severity of neonatal respiratory distress syndrome. *Eur J Radiol* 2019; 116:186–91
  91. Raimondi F, Yousef N, Rodriguez Fanjul J, De Luca D, Corsini I, Shankar-Aguilera S, Dani C, Di Guardo V, Lama S, Mosca F, Migliaro F, Sodano A, Vallone G, Capasso L: A multicenter lung ultrasound study on transient tachypnea of the neonate. *Neonatology* 2019; 115:263–8
  92. Gregorio-Hernández R, Arriaga-Redondo M, Pérez-Pérez A, Ramos-Navarro C, Sánchez-Luna M: Lung ultrasound in preterm infants with respiratory distress: Experience in a neonatal intensive care unit. *Eur J Pediatr* 2020; 179:81–9
  93. Blank DA, Kamlin COF, Rogerson SR, Fox LM, Lorenz L, Kane SC, Polglase GR, Hooper SB, Davis PG: Lung ultrasound immediately after birth to describe normal neonatal transition: An observational study. *Arch Dis Child Fetal Neonatal Ed* 2018; 103:F157–62
  94. Razak A, Faden M: Neonatal lung ultrasonography to evaluate need for surfactant or mechanical ventilation: A systematic review and meta-analysis. *Arch Dis Child Fetal Neonatal Ed* 2020; 105:164–71
  95. Steinhorn R, Davis JM, Göpel W, Jobe A, Abman S, Laughon M, Bancalari E, Aschner J, Ballard R, Greenough A, Storari L, Thomson M, Ariagno RL, Fabbri L, Turner MA, International Neonatal Consortium: Chronic pulmonary insufficiency of prematurity: Developing optimal endpoints for drug development. *J Pediatr* 2017; 191:15–21.e1

96. Alonso-Ojembarrena A, Lubián-López SP: Lung ultrasound score as early predictor of bronchopulmonary dysplasia in very low birth weight infants. *Pediatr Pulmonol* 2019; 54:1404–9
97. Loi B, Vigo G, Baraldi E, Raimondi F, Carnielli VP, Mosca F, De Luca D, LUSTRE (Lung UltraSound To pReTerm nEonates) Study Group: Lung ultrasound to monitor extremely preterm infants and predict BPD: Multicenter longitudinal cohort study. *Am J Respir Crit Care Med* 2020 [Epub ahead of print]
98. Jambrik Z, Monti S, Coppola V, Agricola E, Mottola G, Miniati M, Picano E: Usefulness of ultrasound lung comets as a nonradiologic sign of extravascular lung water. *Am J Cardiol* 2004; 93:1265–70
99. Xie HQ, Zhang WW, Sun S, Chen XM, Yuan SF, Gong ZH, Liu L: A simplified lung ultrasound for the diagnosis of interstitial lung disease in connective tissue disease: A meta-analysis. *Arthritis Res Ther* 2019; 21:93
100. Gargani L: Ultrasound of the lungs: More than a room with a view. *Heart Fail Clin* 2019; 15:297–303
101. Gargani L, Sicari R, Raciti M, Serasini L, Passera M, Torino C, Letachowicz K, Ekart R, Fliser D, Covic A, Balafa O, Stavroulopoulos A, Massy ZA, Fiaccadori E, Caiazza A, Bachelet T, Slotki I, Shavit L, Martinez-Castelao A, Coudert-Krier MJ, Rossignol P, Kraemer TD, Hannedouche T, Panichi V, Wiecek A, Pontoriero G, Sarafidis P, Klinger M, Hojs R, Seiler-Mussler S, Lizzi F, Onofriescu M, Zarzoulas F, Tripepi R, Mallamaci F, Tripepi G, Picano E, London GM, Zoccali C: Efficacy of a remote web-based lung ultrasound training for nephrologists and cardiologists: A LUST trial sub-project. *Nephrol Dial Transplant* 2016; 31:1982–8
102. Gargani L, Pang PS, Frassi F, Miglioranza MH, Dini FL, Landi P, Picano E: Persistent pulmonary congestion before discharge predicts rehospitalization in heart failure: A lung ultrasound study. *Cardiovasc Ultrasound* 2015; 13:40
103. Loutradis C, Sarafidis PA, Ekart R, Papadopoulos C, Sachpekidis V, Alexandrou ME, Papadopoulou D, Efstratiadis G, Papagianni A, London G, Zoccali C: The effect of dry-weight reduction guided by lung ultrasound on ambulatory blood pressure in hemodialysis patients: A randomized controlled trial. *Kidney Int* 2019; 95:1505–13
104. Siriopol D, Voroneanu L, Hogas S, Apetrii M, Gramaticu A, Dumea R, Burlacu A, Sascau R, Kanbay M, Covic A: Bioimpedance analysis *versus* lung ultrasonography for optimal risk prediction in hemodialysis patients. *Int J Cardiovasc Imaging* 2016; 32:263–70
105. Zoccali C, Torino C, Tripepi R, Tripepi G, D'Arrigo G, Postorino M, Gargani L, Sicari R, Picano E, Mallamaci F; Lung US in CKD Working Group: Pulmonary congestion predicts cardiac events and mortality in ESRD. *J Am Soc Nephrol* 2013; 24:639–46
106. Gutierrez M, Soto-Fajardo C, Pineda C, Alfaro-Rodriguez A, Terslev L, Bruyn G, Iagnocco A, Bertolazzi C, D'Agostino MA, Delle Sedie A: Ultrasound in the assessment of interstitial lung disease in systemic sclerosis: A systematic literature review by the OMERACT ultrasound group. *J Rheumatol* 2020; 47:991–1000
107. Gargani L, Doveri M, D'Errico L, Frassi F, Bazzichi ML, Delle Sedie A, Scali MC, Monti S, Mondillo S, Bombardieri S, Caramella D, Picano E: Ultrasound lung comets in systemic sclerosis: A chest sonography hallmark of pulmonary interstitial fibrosis. *Rheumatology (Oxford)* 2009; 48:1382–7
108. Shiraishi J, Li Q, Appelbaum D, Doi K: Computer-aided diagnosis and artificial intelligence in clinical imaging. *Semin Nucl Med* 2011; 41:449–62
109. Brattain LJ, Telfer BA, Liteplo AS, Noble VE: Automated B-line scoring on thoracic sonography. *J Ultrasound Med* 2013; 32:2185–90
110. Raso R, Tartarisco G, Matucci Cerinic M, Pioggia G, Picano E, Gargani L: A soft computing-based B-line analysis for objective classification of severity of pulmonary edema and fibrosis. *JACC Cardiovasc Imaging* 2015; 8:495–6
111. Weitzel WF, Hamilton J, Wang X, Bull JL, Vollmer A, Bowman A, Rubin J, Kruger GH, Gao J, Heung M, Rao P: Quantitative lung ultrasound comet measurement: Method and initial clinical results. *Blood Purif* 2015; 39:37–44
112. Moshavegh R, Hansen KL, Moller-Sorensen H, Nielsen MB, Jensen JA: Automatic detection of B-lines in *in vivo* lung ultrasound. *IEEE Trans Ultrason Ferroelectr Freq Control* 2019; 66:309–17
113. Brusasco C, Santori G, Tavazzi G, Via G, Robba C, Gargani L, Mojoli F, Mongodi S, Bruzzo E, Trò R, Boccacci P, Isirdi A, Forfori F, Corradi F; UCARE (Ultrasound in Critical care and Anesthesia Research Group): Second-order grey-scale texture analysis of pleural ultrasound images to differentiate acute respiratory distress syndrome and cardiogenic pulmonary edema. *J Clin Monit Comput* 2020 [Epub ahead of print]